Laser Trabecular Modulation in Optometry

This article will discuss laser glaucoma treatments and argue the case that SLT is really not surgery but rather Laser Trabecular Modulation and falls within the scope of treatment by specialist optometrists. Perhaps LTM would be a better description?

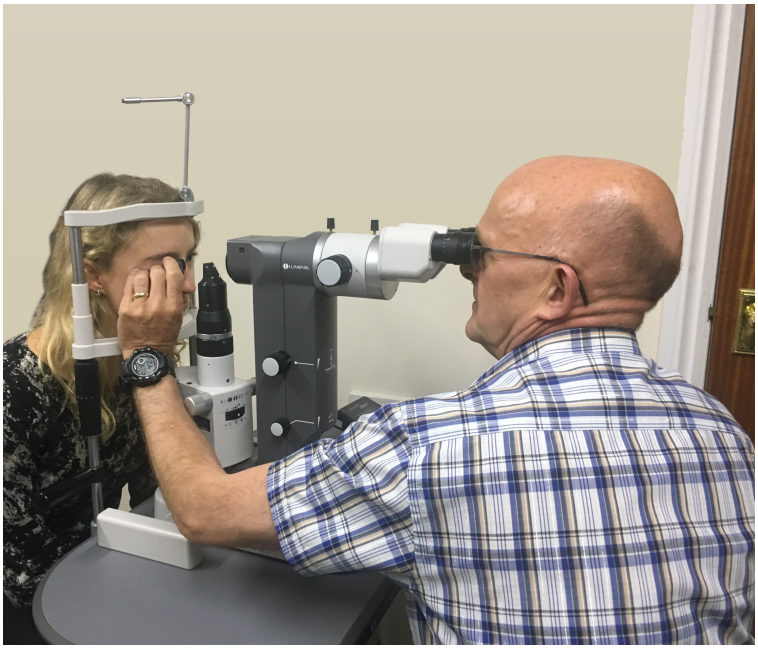

General Treatment Overview

Classically, it has been usual to treat glaucoma and ocular hypertension initially with eye drops such as prostaglandin analogues, adding a second or third drop such as beta-blockers, carbonic anhydrase inhibitors or alpha agonists (which use a different mechanism) if further pressure lowering effect is needed. However, pharmacological options have potential side effects and depend on patient compliance – not missing doses and correctly instilling drops. Many patients treated for glaucoma eventually progress to blindness in one eye. There could be several possible reasons for this, but one of the most likely would be non-compliance with medical treatment. This may be because older patients forget to instil their drops or patients dislike the side effects they cause.

We then turned to laser treatment and then surgery such as trabeculectomy if inadequate control could be obtained with drops alone or ocular allergy, toxicity and/or serious systemic side effects meant the drops had to be discontinued. (The discussion of glaucoma surgery is outside the scope of this article).

It was in the 1970s that various relatively high power lasers were first used to attempt to lower IOP by puncturing the trabecular meshwork down to Schlemm's canal. This went by the name of goniopuncture. Unfortunately, these holes closed within weeks due to fibrous scarring.

In 1979 wise and Witter developed the ALT (Argon Laser Trabeculoplasty) technique in which much lower power laser burns were made to the trabecular meshwork to cause coagulation and tension in the trabecular meshwork. This was called Trabeculoplasty and produced a meaningful and relatively sustained reduction in IOP.

Since the early 2000's, SLT (Selective Laser Trabeculoplasty), which uses far less energy, has largely taken over from ALT.

In addition to avoiding the potential side effects of drugs and relying on patient compliance, patients are less affected by nocturnal IOP spikes post laser Trabeculoplasty as the effect on drainage is constant for the full 24 hr period[6]. Generally, ALT or SLT can replace one glaucoma medication, often the prostaglandin analogue[2].

ALT utilises an Argon Green gas laser, whereas the Nd:YAG laser used in SLT is a solid state Q-switched, frequency-doubled laser. The Q-switched Nd:YAG laser can deliver the very short pulses of light required for SLT. (The same laser Nd:YAG can also be used in its non-frequency doubled, 1064nm mode for photo-disruptive treatments such as YAG capsulotomy and peripheral iridotomy).

Both ALT and SLT are discussed further below.

Laser Treatment Overview

Laser Trabeculoplasty is the most common laser procedure in open angle glaucoma. Several studies show the effectiveness of laser Trabeculoplasty in IOP control in glaucoma[1]. Initially we had Argon Laser Trabeculoplasty (ALT) in the 1990's which was used into the early 2000's. Since which point Selective Laser Trabeculoplasty (SLT) has largely taken over. Two other variants are Micro Pulse Diode Laser Trabeculoplasty (MDLT) and Titanium/Sapphire Laser Trabeculoplasty (TSLT) which are not discussed in this article. Another novel variation on SLT is to use the trans-scleral route, though I have not seen this done. The SLT is applied to the sclera overlying the trabecular meshwork. This is reported to produce an equivalent IOP reduction to conventional SLT.

Expected IOP reduction with ALT or SLT is normally 20-30% as a primary procedure. At 5 years it is effective in 50% of cases and 30% at 10 years. It tends to be very effective for the first 1-3 years with the effect waning after this period, meaning a repeat procedure is required in these cases[14.] (It should be noted, however, that with ALT, any repeat procedure can only be performed on areas not already treated – see below.)

ALT treatment initially involved placing a series of small high energy laser burns in the anterior portion of the pigmented trabecular meshwork. (180 degrees?) These cause thermal damage and shrinkage of the trabecular meshwork opening up intra-trabecular spaces improving aqueous drainage and lowering the intra-ocular pressure[11].

Electron microscopy of the trabecular meshwork after ALT in the left hand image of below, clearly shows the laser burn, whereas in the right hand image following SLT there is no coagulation or destruction, merely an open trabecular meshwork.

The destruction with ALT seen in the left hand image is key to the pressure lowering effect as contraction of scar tissue pulls the untreated remaining trabecular structure open. The SLT treated eye by comparison has a normal trabecular meshwork appearance, the IOP lowering in this instance being due to the mobilisation of macrophages which clean up all the pigment etc, increasing its permeability.

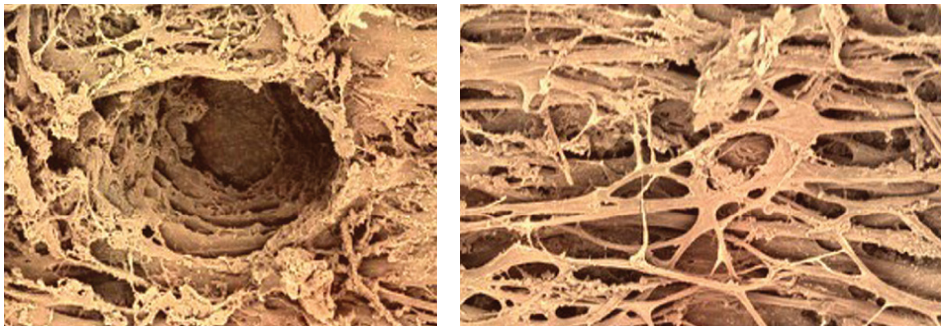

Images from a scanning electron microscope showing the damage to the TM after ALT [left] compared to SLT

Because the treated area has been permanently modified in ALT, a treated area once burnt can not be retreated. In fact, retreating, could eventually lead to synechial angle closure and a decrease in outflow facility[7, 8, 9,10,11,].

Additional problems specific to ALT include anterior synechae and pain if the high intensity burn is placed too close to the iris or ciliary body. Rarely ALT causes angle bleeding. This is normally transient and controlled by exerting pressure with the goniolens until clotting occurs. Corneal clouding can occur if high energy ALT burns are placed too anteriorly, especially in a narrow angle.

Contraindications and Adverse reactions

Both ALT and SLT require less energy to be used in heavily pigmented trabecular meshworks. In cases of PDG and PXE extra care is required to ensure that over-treatment does not occur. Many advocate treating only a few degrees initially to judge the reaction to treatment, before proceeding to treat a further section. These patients often will end up with 45-180 degrees being treated[18].

Other contraindications to laser trabecular treatments include advanced POAG, where a post-treatment pressure spike might “snuff out” part of the remaining visual field, angles too narrow to view the trabecular meshwork even with miotics, neovascular or inflammatory glaucoma, angle recession or an excessively hazy cornea[19]. SLT can act as a stimulus for increased vascular proliferation in neovascular glaucoma. Corneal opacity from scarring, dystrophy etc can make visualisation of the angle during treatment and could absorb laser energy and cause

corneal damage. In cases of excessive corneal oedema such as in Bullous Keratopathy, hypertonic saline can be used for some days beforehand to improve corneal clarity.

The most common adverse reactions in both ALT and SLT are an IOP spike or anterior uveitis after treatment. Normally apraclonidine or brimonidine drops are instilled before and after treatment to reduce immediate post surgical pressure spikes. Some practitioners would instil Ketorolac NSAID or dexamethasone steroid drops afterwards to reduce anterior chamber activity inflammation. Conversely, others would recommend not doing so unless absolutely necessary as the SLT treatment is attempting to up-regulate inflammatory activity in the trabecular meshwork and steroids especially may interfere with this process.

SLT

The recent NICE Light Study[1] recommends that SLT is used as an early intervention, ideally in many cases, instead of eye drops to treat POAG and ocular hypertension. The American Academy of Ophthalmology preferred practice guidelines also state "Laser Trabeculoplasty can be considered as initial therapy in selected patients".

Gus Gazzard, Moorfields Eye Hospital Glaucoma Consultant.

Not only is SLT equally effective or better than many existing first line drug treatments, it represents a major saving compared to the cost of eye drops and a significant improvement in patient lifestyle with freedom from eye drops[1,2,3]. It has been estimated that if all newly diagnosed cases are treated with SLT rather than drops the NHS will save £1.5m annually[1]. The savings would be many times more if SLT was introduced for existing glaucoma patients already under treatment.

SLT is more effective if eye drops have not been used beforehand.

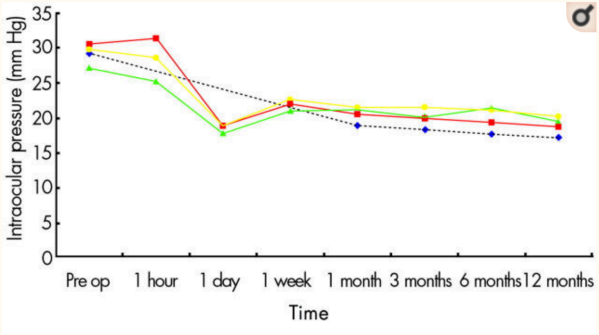

Open in a separate window

Figure 1

Intraocular pressure over time with treatment with latanoprost (blue diamonds), 90° SLT (green triangles), 180° SLT (yellow squares), and 360° SLT (red squares).

The above graph from the Nagar study[12] shows the effect of 360 SLT is comparable to topical latanaprost.

The full IOP lowering effect is often not seen until 4-6 weeks after treatment. In an established glaucoma patient under treatment, medication currently in use is often continued for the first month or so and then reduced if no longer required. Some advocate stopping prostaglandins prior to SLT as they have a similar biologic effect on the trabecular meshwork as SLT and instead changing to a drop with a different mode of action, until the full effect of the SLT has developed. The use of pilocarpine may improve the surgeon's access to angle structures as well as mitigate postoperative elevations in IOP.

The similar biologic effect of prostaglandin analogues to SLT can be used to predict patients who are likely to be successful with SLT treatment[8]. Newly diagnosed glaucoma and ocular hypertensive patients whose pressure drops well in response to evaluative prostaglandin drops are likely to do well with SLT[2]. In the same vein, patients already on prostaglandins are unlikely to get so much additive pressure lowering effect from having SLT treatment compared with those on say on a beta-blocker. Patients who need further IOP reduction after SLT would probably be better treated with a different family of glaucoma drops to the prostaglandins.

SLT works better in patients who have a higher presenting IOP. Several SLT studies show an average of only 15% reduction in IOP in NTG, which is probably not unexpected. However, the reduction in nocturnal IOP spikes was still thought to be highly beneficial[23].

Energy Levels in SLT – is it Surgery?

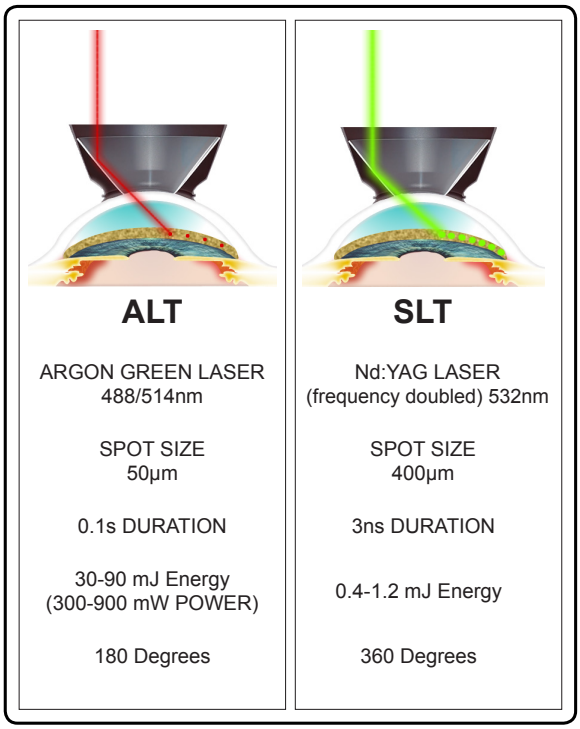

Many currently consider SLT a form of “surgery”. This probably was a valid opinion as far as the earlier technique of ALT was concerned as in this process a high power spot of laser energy (normally of the order of 600w (600 mJ/sec) over a 50 micron spot size) is focussed onto the trabecular meshwork, where it causes laser burns that cause scarring and shrinkage of the adjacent trabecular meshwork, opening it up to improve drainage. This tightening effect is similar to the effect on the trabecular meshwork after cataract extraction.

The laser stimulation in SLT is, however, used at very low energy levels of often less than 0.5 mJ, for only a 3nsec treatment time, over a much larger spot size of 400 microns. This by my calculations, means that the spot intensity is an amazing 10^{12} (i.e. a **trillion**) times weaker in SLT than ALT.

The short treatment pulse means that the there is not enough time for the melanin trabecular pigment to convert the electromagnetic laser energy into heat energy. This is because the thermal relaxation time of melanin is 1 microsecond, many times longer than the 3 nanoseconds duration of the SLT pulse. It exerts a “COLD” “biologic” effect in which the laser energy activates chemical mediators that attract macrophages and other phagocytes that then clean up the debris in the trabecular meshwork, thereby improving its throughput of aqueous, lowering the IOP.

The Equipment Used

The new Rapid SLT lens

Two of the main laser gonio lenses used for SLT are the original single mirror Latina lens developed by Mark Latina, one of the original pioneers of SLT[22] and the amazing newVolk Rapid SLT 4 mirror lens. This lens does exactly what it says on the box, enabling you to rapidly treat the whole 360 degrees of the trabecular meshwork, only having to rotate the lens 22.5 degrees once. The multiple angle view makes the whole procedure very quick and improves the patient experience. As there is no blanching with SLT treatment the new lens makes it easier not to lose the location you are treating because the lens is only rotated once during treatment.

The original Latina Lens

SLT – A breakdown of the technique

- Anterior eye exam/gonioscopy to rule out contraindications such as neovascular glaucoma, uveitis, plateau iris, angle recession, anterior synechae etc
- Educate/counsel patient
- Sign informed consent form
- Instil apraclonidine or brimonidine drops 15 mins before starting
- Instil pilocarpine if angle narrow or iris has convex profile
- Instil topical anaesthetic, e.g. benoximate
- Use 16x to 25x magnification
- Start treating whole 360 degrees of trabecular meshwork, with approx 25 treatment spots per quadrant, using the min energy/power setting to obtain small bubble formation and then reduce energy level by 0.1mJ so bubble formation does not occur. This needs regular titrating of power settings as requirements will vary depending on pigmentation in different quadrants. With SLT you do not want to see pigment blanching. In more pigmented eyes fewer clock hours are treated initially as the effect is likely to be stronger.
- Avoid areas of anterior synechae, physiological blood vessels.
- After gonio lens is removed, instil a further drop of apraclonidine or brimonidine
- Optional Ketorolac NSAID or Dexamethasone Steroid drops for 1/52, or as required
- Check IOP 15-30 minutes later
- Review in 1-2 weeks, check for IOP and lack of anterior chamber activity
- Review 6 weeks, consider reducing glaucoma drops
- 2nd eye is usually treated at this point once full effect on first eye has been evaluated.

Optometrists and SLT?

SLT is considered by many relatively straight forward to perform as the precise location of the patch of laser stimulation is not so critical owing to the larger spot size and its lower intensity. The whole width of the trabecular meshwork is irradiated in SLT with a low intensity laser light. In ALT a small, high intensity spot has to be focussed on the anterior aspect of the pigmented trabecular meshwork. In ALT usually 180 degrees is initially treated with 50-60 burns approximately 2 spot diameters apart. SLT by comparison usually treats 360 degrees with 100 treatment spots.

There have been further studies that show that SLT can work effectively at even lower energy levels than the normal 0.8mJ[15]. In this study very low energy SLT (0.2-0.4mJ) performed annually gave effective IOP control in 85% of patients at 5-7 years, compared to 47% with conventional SLT on an “as needed” basis and 38% with ALT treatment.

The two main stumbling blocks to its universal adoption as a first line treatment is the initial cost of the laser and the professional time demands to implement it. As with intra-vitreal injections, I feel this is where therapeutic optometrists can rise to the occasion requiring only a moderate amount of additional training to build on their already impressive slit-lamp skills. Glaucoma specialist therapeutic qualified optometrists are an obvious first cohort to perform a pilot study to prove to ophthalmology that we can provide this service both safely and cost effectively.

Over 300 optometrists are therapeutically qualified (DipTpIP) and 30-40 have specialist higher glaucoma management (DipGlauc). If they have both qualifications, they are entitled to independently treat ocular hypertension, (raised intra-ocular pressure that is likely to progress to glaucoma if not treated), and to independently manage established glaucoma once an ophthalmologist has made the initial diagnosis and referred the patient to the Glaucoma Specialist Independent Prescribing Optometrist

Hopefully, if enough therapeutic optometrists get accreditation and experience in these techniques and enough of our broader minded ophthalmology colleagues get behind us, optometrist led Glaucoma/Ocular Hypertension treatment with laser can become a reality.

Owing to the low power used, the technique in SLT is safe, accuracy of placing the treatment spot is less critical and gonioscopy is a skill most specialist optometrists already possess. A study by Nisha and Teng evaluated how long the learning curve was to perform SLT. They found that there was no difference in outcomes between a trainee doctor’s performance of their first SLT procedure, compared to later cases. This would imply that it would be well within the remit of a suitably trained specialist optometrist.

SLT should be re-defined as being non-surgical as no coagulation, burning, or photodisruption occurs (i.e. no change in structure is induced) during treatment. Perhaps it should have a new name? Perhaps LTM (Laser Trabecular Modulation) which reflects more truly what is actually happening. If this redefinition is accepted by the various authorities concerned, it is likely that LTM (or whatever it ends up being called), could be classified as non-surgical, like IPL and able to be performed by suitably accredited optometrists.

Glaucoma Specialist Therapeutic Optometrists currently treat and manage established glaucoma patients referred to them by ophthalmologists~~, currently with drugs,~~ and independently diagnose and preventively treat patients with elevated eye pressure that has not progressed to glaucoma as yet (i.e. ocular hypertensives), thereby avoiding them suffering unnecessary loss of sight. Current treatment is mainly with eye drops, however using SLT means that a patient may have adequate pressure control to prevent glaucoma medication for 2-5 years, after which time it can be repeated as no laser damage has been done to the trabecular meshwork during treatment.

In many ways SLT is similar to the light and laser therapies offered by many beauticians in high streets. Laser Trabecular Modulation uses much lower energy levels than optometrists currently use in IPL to treat dry eye and Meibomian Gland Dysfunction.

Often therapeutic optometrists are the first port of call for ocular emergencies, using steroid and non-steroidals to treat inflammatory conditions such as Cystoid macular oedema and anterior uveitis, antibiotics for infective disease and ocular hypertensives both oral and eye drop to control both chronic and acute raised intra-ocular pressure. In the course of anti-VEGF treatment, I use drugs such as iopidine and brimonidine to prevent pressure spikes. I am proficient at lowering IOP post injection with ocular massage. In the hospital environment, I have injected intra-vitreal pellets and performed paracentesis. I work closely with ophthalmology both in the NHS and private sectors.

All these things are clinically more demanding than performing and managing SLT. Drugs that are commonly used include miotics, steroids and ocular hypertensives, well within the remit of a suitably trained and experienced therapeutic optometrist.

SLT (possibly renamed LTM?) gives us a tool to improve patients lives, often by completely freeing them from the need to instil eye drops possibly for up to 5 years between treatments. Its adoption will reduce the number of adverse reactions and side effects to medication, enable better nocturnal control of IOP fluctuations, eliminate non-compliance problems and save the patient or the NHS massive expenditure.

In order to achieve full benefit for the patient and the NHS, it is vital that there are enough people able to provide the service.

Suitably trained and qualified optometrists are able to provide this treatment conveniently, safely and cost effectively. This will reduce the need for so many hospital review appointments and free our ophthalmology colleagues up for more demanding tasks.

We need to push for this to happen, both in the HES and in private practice.

Andrew Matheson is a Glaucoma Specialist Therapeutic Optometrist involved in glaucoma management and providing hospital laser surgery services

Refs

1. Laser in Glaucoma and Ocular Hypertension(LIGHT) Study – Gazzard et al, Lancet March 2019.
2. Katz LJ, Steinmann WC, Marcellino G, SLT/MED Study Group. Presented at the American Academy of Ophthalmology annual meeting. November 2006.
3. The SLT Med Study, Katz LJ et al, Journal of Glaucoma, sept 2012, 460-468
4.
5. Francis BA, Ianchulev T, Schofield JK, Minckler DS. Selective laser Trabeculoplasty as a replacement for medical therapy in open angle glaucoma. *Am J Ophthalmol.* 2005;140(3):524-525.
6. Lee AC, Mosaed S, Weinreb RN, Kripke DF, Liu JH. Effect of laser Trabeculoplasty on nocturnal intraocular pressure in medically treated glaucoma patients. *Ophthalmology.* 2007;114(4):666-670.
7. Bradley JM, Anderssohn AM, Colvis CM, et al. Mediation of laser Trabeculoplasty-induced matrix metalloproteinase expression by IL-1beta and TNF-alpha. *Invest Ophthalmol Vis Sci.* 2000;41(2):422-430.
8. Acott TS, Samples JR, Bradley JM, Bacon DR, Bylsma SS, Van Buskirk EM. Trabecular repopulation by anterior trabecular meshwork cells after laser Trabeculoplasty. *Am J Ophthalmol*. 1989;107(1):1-6.
9. Dueker DK, Norberg M, Johnson DH, Tschumper RC, Feeney-Burns L. Stimulation of cell division by argon and Nd:YAG laser Trabeculoplasty in cynomolgus monkeys. *Invest Ophthalmol Vis Sci*. 1990;31(1):115-124.
10. Alvarado JA, Alvarado RG, Yeh RF, Franse-Carman L, Marcellino GR, Brownstein MJ. A new insight into the cellular regulation of aqueous outflow: how trabecular meshwork endothelial cells drive a mechanism that regulates the permeability of Schlemm's canal endothelial cells. *Br J Ophthalmol*. 2005;89(11):1500-1505.
11. Kramer TR, Noecker RJ. Comparison of the morphologic changes after selective laser Trabeculoplasty and argon laser Trabeculoplasty in human eye bank eyes. *Ophthalmology.* 2001;108(4):773-779.
12. Nagar M, Ogunyomade A, O'Brart DP, et al. A randomized, prospective study comparing selective laser Trabeculoplasty with latanoprost for the control of intraocular pressure in ocular hypertension and open angle glaucoma. *Br J Ophthalmol.*2005;89(11):1413-1417.
13. Latina MA, Park C. Selective targeting of trabecular meshwork cells: in vitro studies of pulsed and CW laser interactions. *Exp Eye Res.* 1995;60(4):359-371.
14. The Glaucoma Laser Trial Research Group. The Glaucoma Laser Trial (GLT). 2. Results of argon laser Trabeculoplasty versus topical medicines. *Ophthalmology.* 1990;97(11):1403-1413.

15. Low-power Annual SLT Effective for Ocular Hypertension, Medscape, May 19th, 2014. Gandolfi & Fechtner).
16. Mao AJ, Pan XJ, McIlraith I, Strasfeld M, Colev G, Hutnik C. Development of a prediction rule to estimate the probability of acceptable intraocular pressure reduction after selective laser Trabeculoplasty in open-angle glaucoma and ocular hypertension. J Glaucoma. 2008;17(6):449-454.
17. Latina MA, Park C. Selective targeting of trabecular meshwork cells: in vitro studies of pulsed and CW laser interactions. Exp Eye Res. 1995;60(4):359-371.
18. Ayala M, Chen E. Comparison of selective laser Trabeculoplasty (SLT) in primary open angle glaucoma and pseudoexfoliation glaucoma. Clin Ophthalmol. 2011;5:1469-1473.
19. Ayala M, Chen E. Predictive factors of success in selective laser Trabeculoplasty (SLT) treatment. Clin Ophthalmol. 2011;5:573-576.
20. Hodge WG, Damji KF, Rock W, Buhrmann R, Bovell AM, Pan Y. Baseline IOP predicts selective laser Trabeculoplasty success at 1 year post-treatment: results from a randomised clinical trial. Br J Ophthalmol. 2005;89(9):1157-1160.
21. Hong BK, Winer JC, Martone JF, Wand M, Altman B, Shields B. Repeat selective laser Trabeculoplasty. J Glaucoma. 2009;18(3):180-183.
22. G Clews. Has the SLT light study shed new light on treating eye conditions? Acuity, summer 2019
23. Tojo N, Oka M, Miyakoshi A, Ozaki H, Hayashi A. Comparison of fluctuations of intraocular pressure before and after selective laser Trabeculoplasty in normal-tension glaucoma patients. J Glaucoma 2014; 23(8): e138–e143.
24. Belkin M., ARVO Annual Meeting Abstract | April 2014 Annual Meeting Abstract | April 2014, Direct Trans-Scleral Selective Laser Trabeculoplasty
25. Nisha C & Teng C, resident performed SLT in patients with OAG, Glaucoma Today, Jan/Feb 2015.